



# Restoration Of Endodontically Treated Teeth

Prepared by :

**Dr. Zahra Norouzi**

Assistant professor of shahrekord dental school

2022/Mar



# Introduction




- ▶ Endodontic treatment is largely performed on teeth significantly affected by caries, multiple repeat restorations and/or fracture.
- ▶ Already structurally weakened, such teeth are often further weakened by the endodontic procedures designed to provide optimal access and by the restorative procedures necessary to rebuild the tooth.
- ▶ It is therefore accepted that endodontically treated teeth are weaker and tend to have a lower lifetime prognosis.




# INTRODUCTION



- ▶ Hence require special considerations for the final restoration, particularly where there has been extensive loss of tooth structure.
- ▶ The special needs involve ensuring both adequate retention for the final restoration and maximum resistance to tooth fracture.
- ▶ Endodontic success depends not only on the quality of the root canal treatment, but also on timely coronal restoration of the compromised tooth.



# What are the objectives of Final restoration?

- ▶ Maintained coronal seal of the root canal treatment
  - ▶ Protect and preserve the remaining tooth structure
  - ▶ Provided a supportive and retention foundation for the placement of definitive restoration
  - ▶ Restore the function and aesthetics
- 




# Treatment plan

The choice of the therapeutic option when restoring a devitalized tooth is based on several factors.

- ▶ Amount of remaining sound tooth structure
- ▶ The geometry of the tooth cavity,
- ▶ Position of the tooth in the arch
- ▶ Esthetics
- ▶ Occlusal function, Opposing dentition, Parafunctions in the occlusal context,
- ▶ Length, width and curvature of the roots
- ▶ Endodontic/periodontal prognosis,
- ▶ The financial aspects



# Risk assessment

- 
- ▶ Proximal contact
  - ▶ Exposure to oral fluid
  - ▶ Retention & resistance
  - ▶ Ferrule
  - ▶ Biologic width
  - ▶ Shape of the root
  - ▶ Force eruption / Crown lengthening
  - ▶ Questionable prognosis

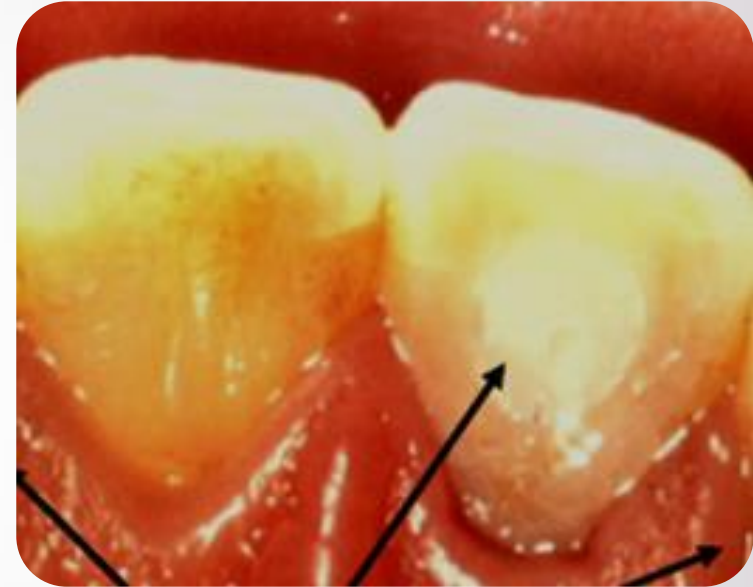


# Treatment choices

- ▶ Direct restoration
  - ▶ Core & crown
  - ▶ Post & core & crown
  
  - ▶ New method
    - ▶ Partial crown
    - ▶ Endocrown
- 

# Anterior teeth

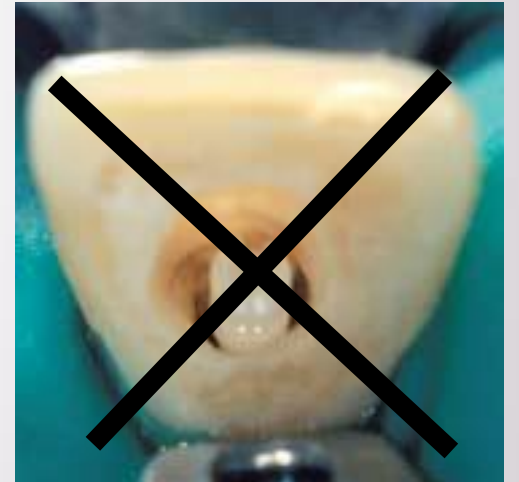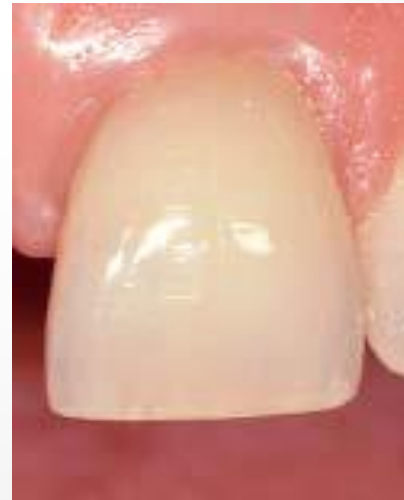- Anterior teeth with minimal loss of tooth structure can be restored conservatively with a bonded restoration in the access opening






# Anterior teeth

- A post is of little or no benefit in a structurally sound anterior tooth
- Increases the chances of a failure

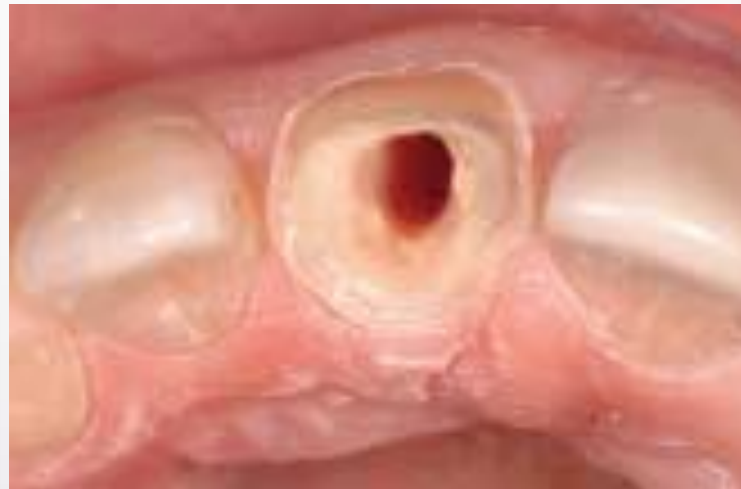
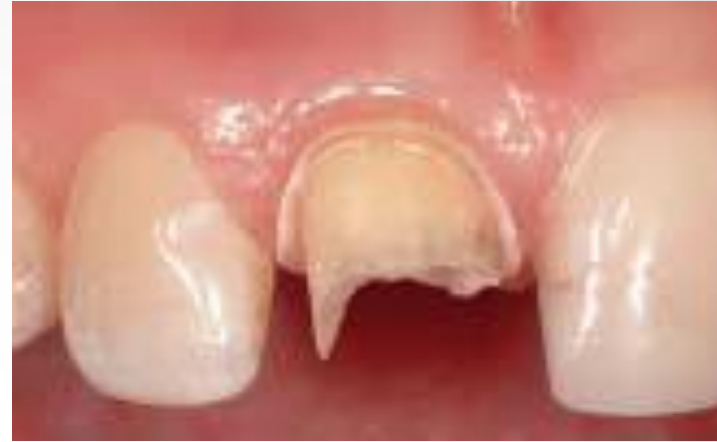
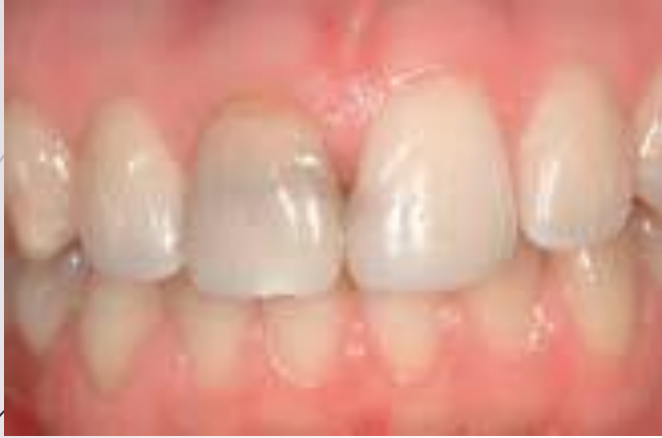

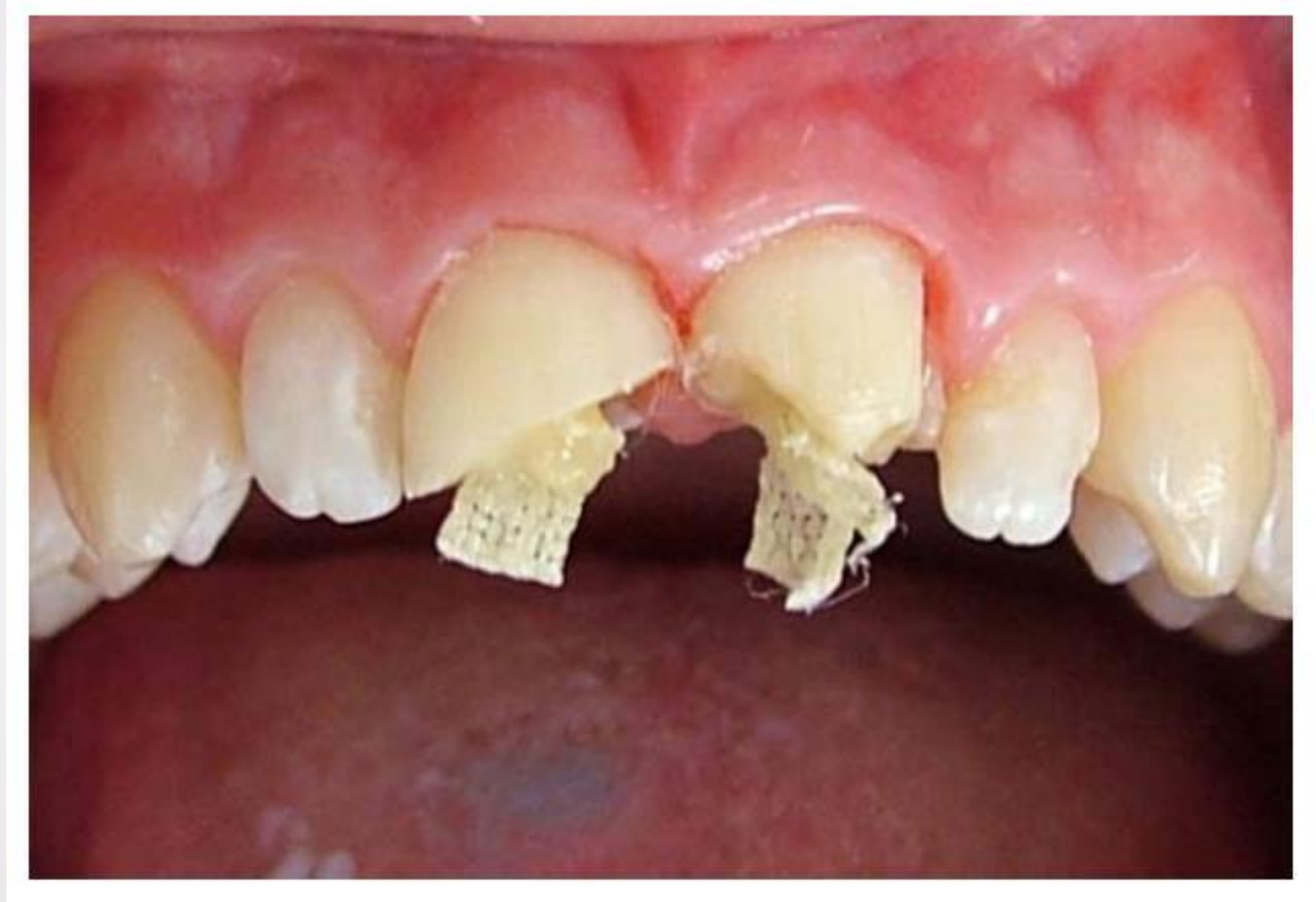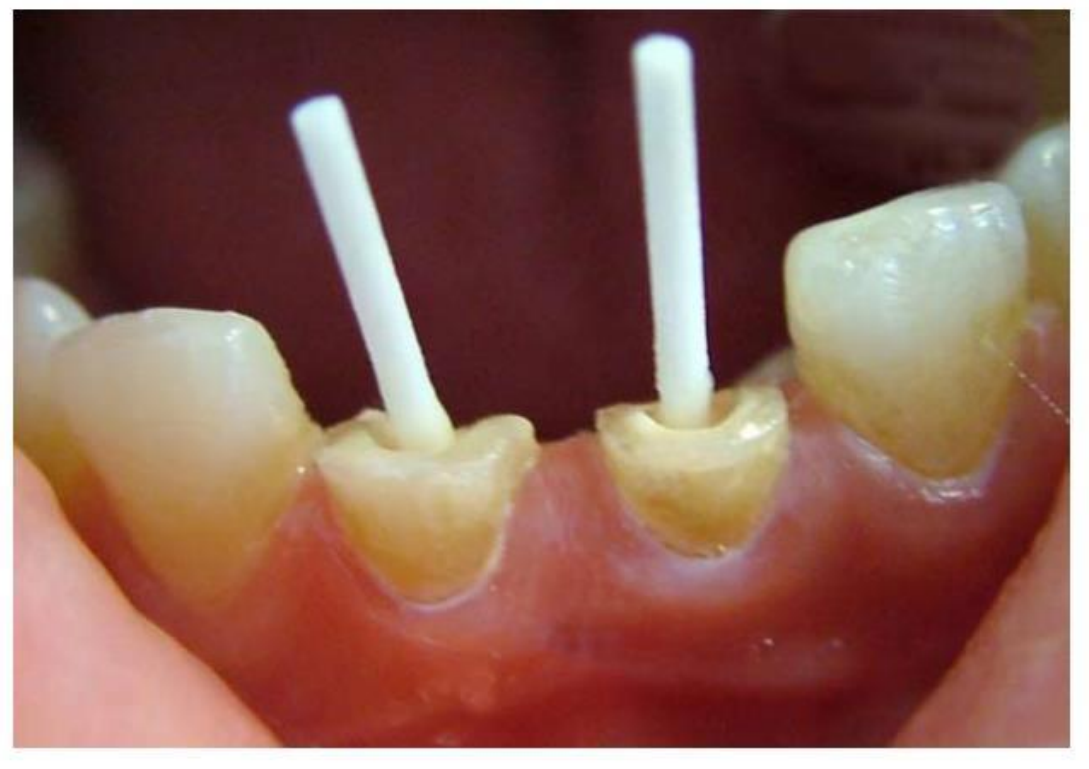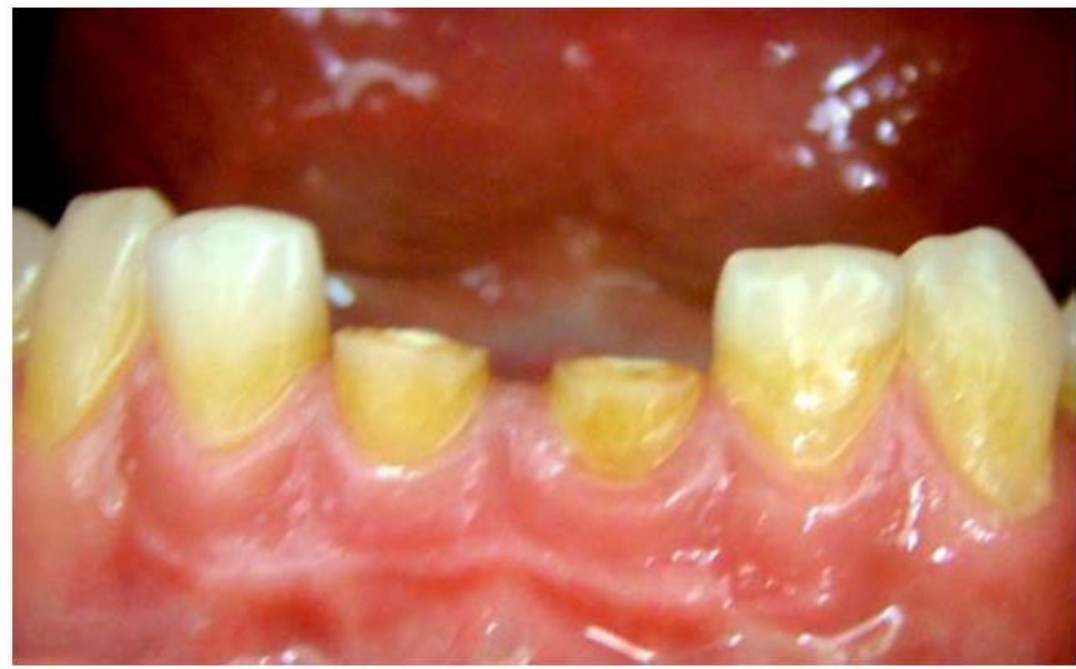# Anterior teeth

- In cases of extensive loss of external tooth structure, a **post** is usually required for anterior teeth, due to the predominantly **shearing** forces present and the **narrow** tooth dimensions.
  - Extra-coronal crown preparation combined with endodontic access preparation significantly weakens the cervical area of anterior teeth.
- 

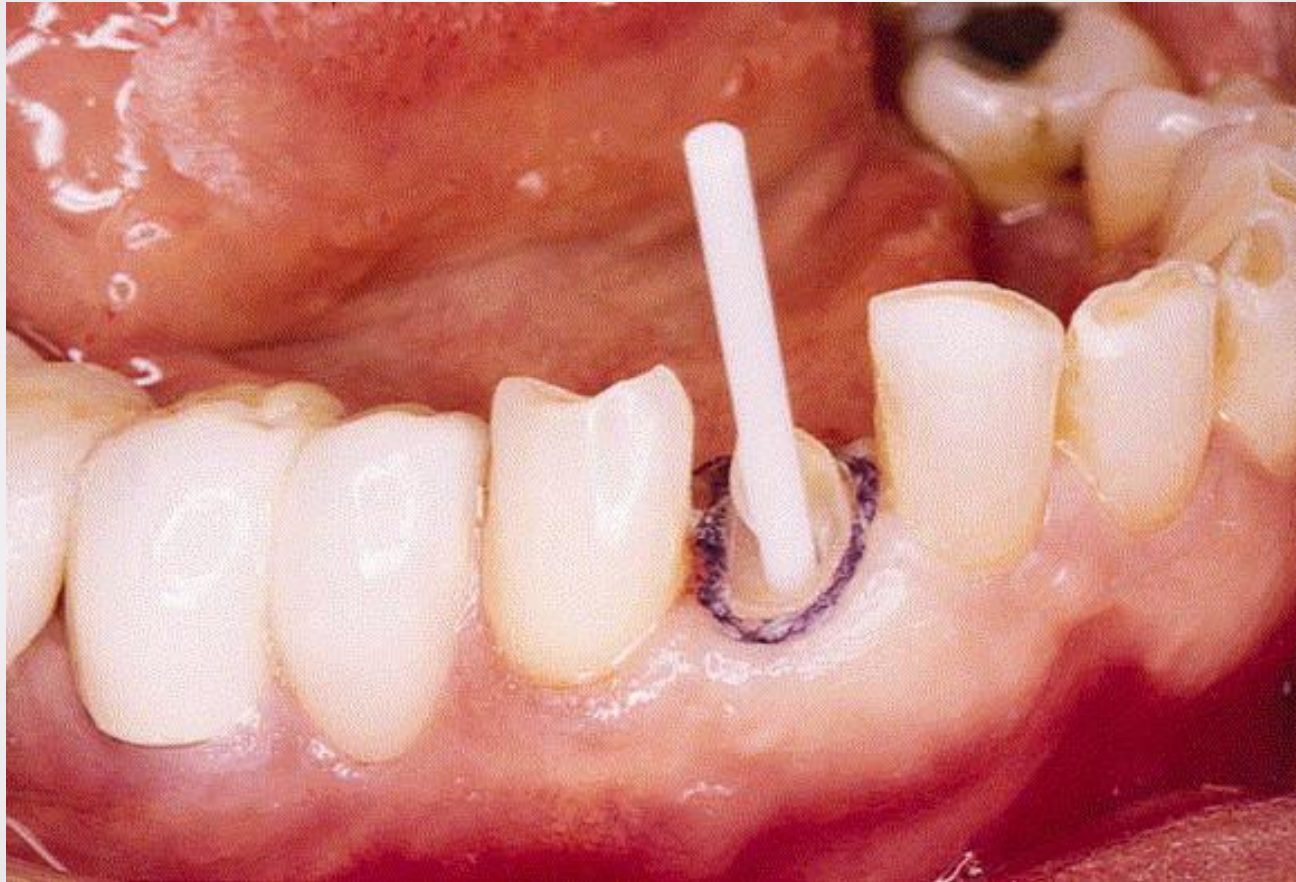
# Anterior Teeth

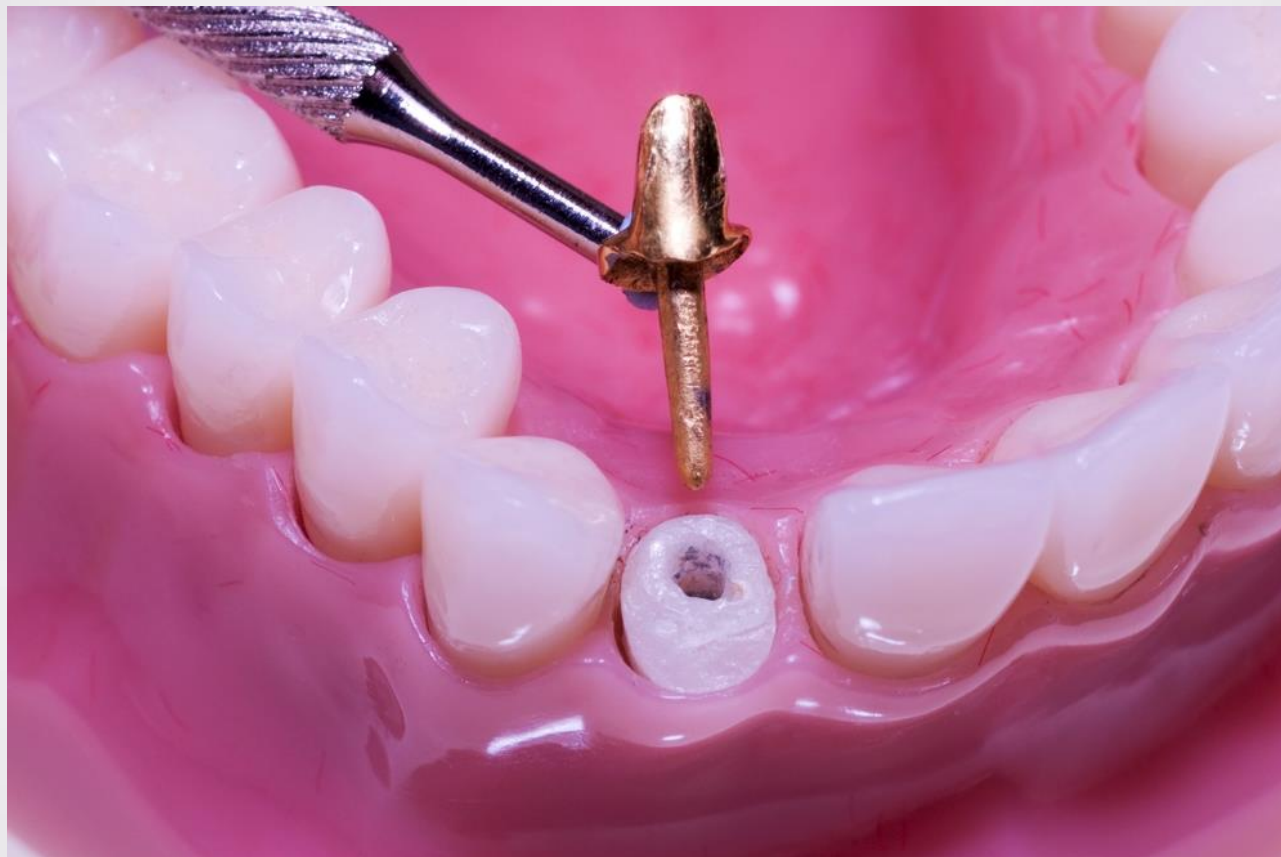


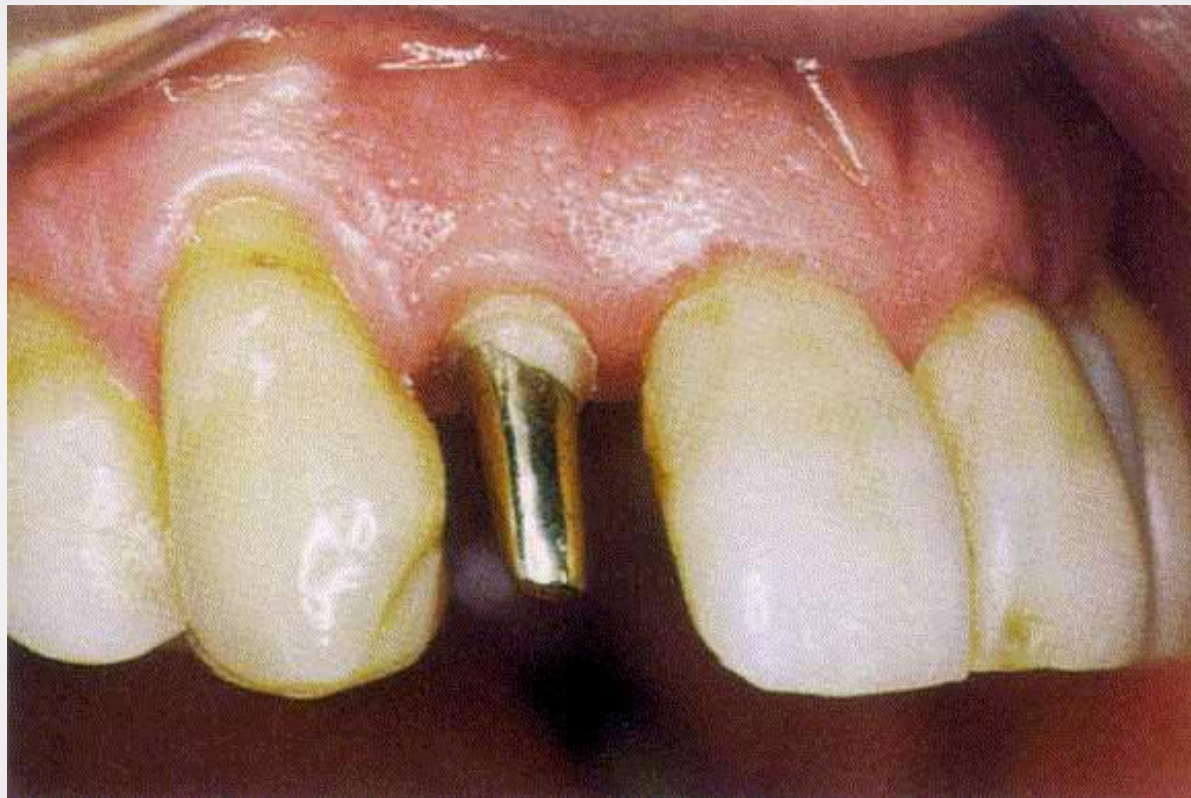




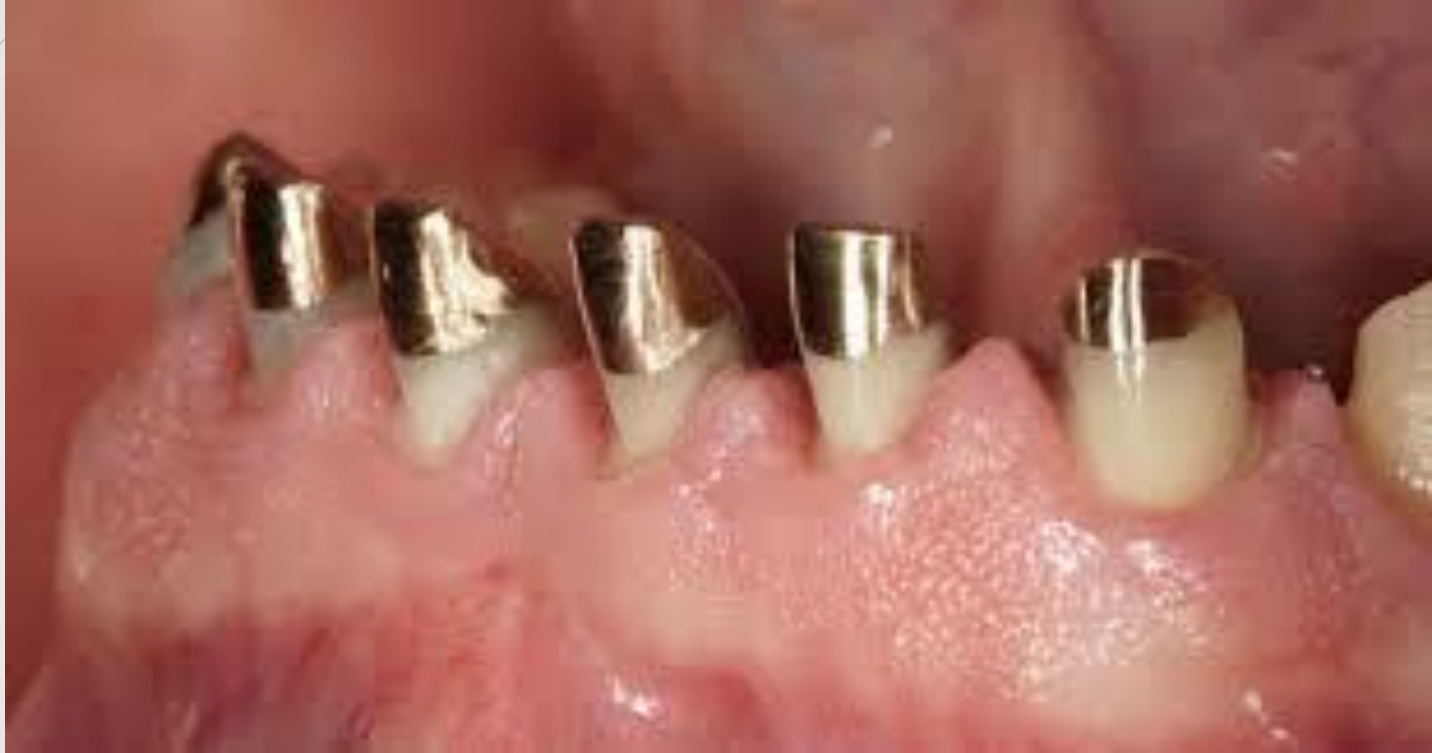




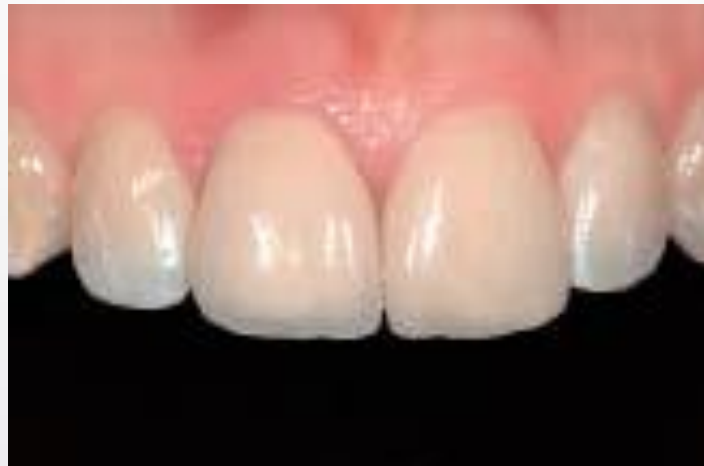
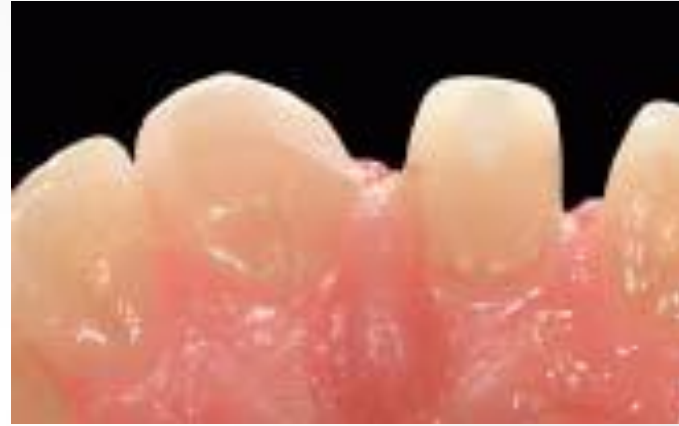
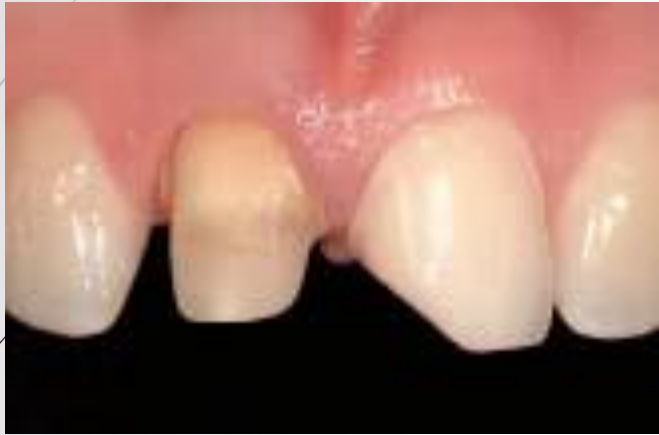



# Anterior Teeth







# Considerations for posterior teeth

- ▶ Endodontically treated posterior teeth are subject to greater loading than anterior teeth, because of their position closer to the insertion of the masticatory muscles.
  - ▶ This, combined with their morphologic characteristics, makes them more susceptible to fracture.
- 

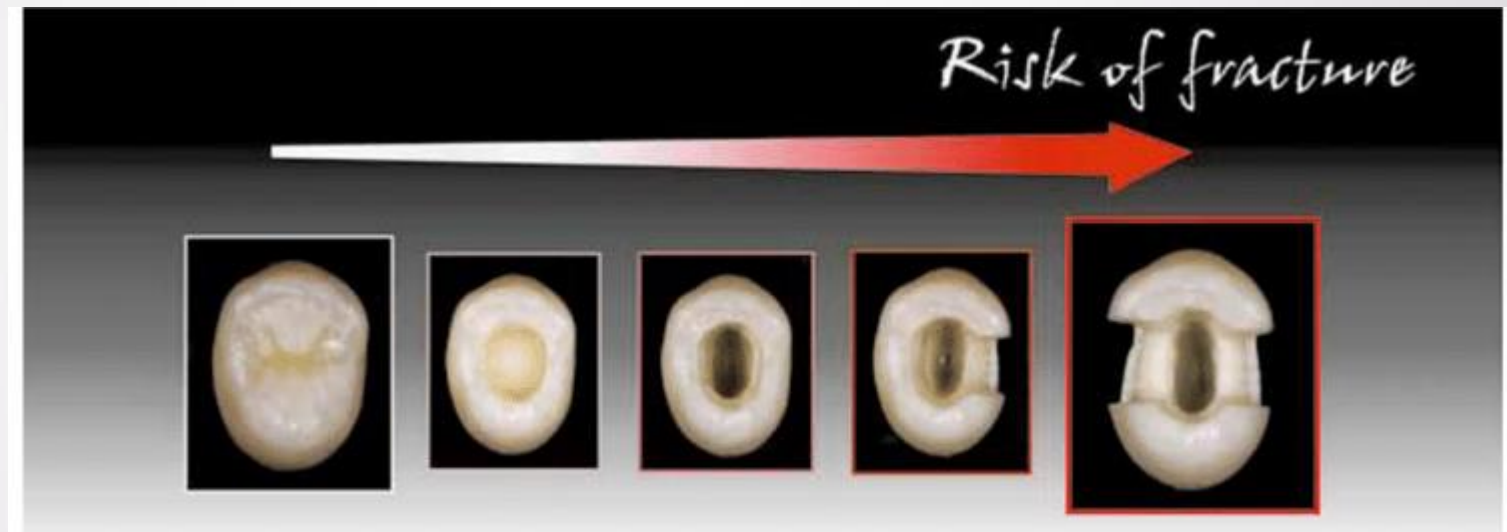


# Posterior teeth

- ▶ With the vast advances in adhesive dentistry, multiple restorative treatment options are available nowadays to restore endodontically treated teeth (ETT).
- ▶ However, determining whether cuspal coverage is needed or not, followed by selecting a suitable treatment option for each clinical situation, could be challenging for the restorative dentist.
- ▶ Conventional methods of restoring teeth, which depend on mechanical retention, are being replaced by modern methods which depend on adhesion.
- ▶ This shift was attributed to the increased popularity of the minimally invasive dentistry philosophy, and the development of reliable adhesive systems, as well as the etchable ceramics



<b>Conventional methods (mechanically retained)</b>	<b>Modern methods (adhesively retained)</b>
Amalgam restorations	Composite restorations
Full- and partial-coverage crowns	Adhesive onlays and overlays
Metal post-core-crown	Fiber post-core-crown
Nayyar core-crown	Endocrowns



**Fig 1** The risk of fracture of an endodontically treated tooth is directly related to the quantity of tissues lost and to the specific cavity configuration.



# Restorative Decision-Making Protocol

- ▶ **Step 1: Assessment of the amount of tooth structure loss and any modifying factors**

The assessment should be done after removal of any caries or old restorations and after finishing an endodontic access cavity when needed.

- ▶ Understanding which part of the tooth structure is most important in keeping its **fracture resistance and stiffness** is fundamental for an accurate assessment of the strength of the remaining tooth structure.
  - ▶ *The marginal ridges*
  - ▶ *The buccal and palatal/lingual axial walls*
  - ▶ *The endodontic access cavity*

# The marginal ridges

- ▶ The marginal ridge has been shown to be critical in the maintenance of tooth **stiffness and limiting excessive cuspal deflection**.
- ▶ the loss of tooth stiffness was:
  - ▶ 20% for an occlusal cavity,
  - ▶ 45% for a mesio-occlusal (MO)/disto-occlusal (DO) cavity and
  - ▶ 63% for a MO-distal (MOD) cavity.
- ▶ it was reported that a **marginal ridge thickness of >1 mm** in maxillary premolar preserved the fracture resistance of the teeth.
  - ▶ Whereas, a **0.5-mm marginal ridge** thickness led to a significant reduction in the tooth fracture resistance compared to the level of intact teeth.
- ▶ The removal of both marginal ridges in MOD cavity preparation produced a dramatic increase in **cuspal deflection** compared to MO/DO cavity preparation.






# *The buccal and palatal/lingual axial walls*

- ▶ The wider the cavity preparation, the thinner the remaining axial walls' thickness.
- ▶ The remaining wall thickness was reported to be an important factor in the resistance to fracture under occlusal load.
- ▶ An axial wall **thickness of <2 mm** was noted to reduce the tooth resistance to fracture in endodontically treated premolars, and it was suggested that **cuspal coverage** would be needed to improve the fracture resistance




# *The endodontic access cavity*

- ▶ A reduction of only 5 -20 % of tooth stiffness was measured when a conservative to wide endodontic access cavity was carried out.
  - ▶ the fracture resistance of teeth with conservative access cavities alone was close to that of an intact tooth.
  - ▶ However, another study reported an increase of 2–3 folds of cuspal deflection when an endodontic access cavity was carried out for MO/DO and MOD cavities.
- 



# Step 1: Classification of posterior teeth

- ▶ The classification sets the posterior teeth into one of the three categories depending on the amount of tooth structure lost.
    - ▶ minimally destructed teeth,
    - ▶ moderately destructed teeth, and
    - ▶ severely destructed teeth
- 



# Minimally destructed ETT

- ▶ Minimally destructed ETT were defined as teeth with
  - ▶ an occlusal cavity or
  - ▶ a MO/DO cavity with thick remaining axial walls ( $\geq 2$  mm).
- ▶ This category of teeth does not necessarily require cuspal coverage to have good longevity.



# Moderately destructed ETT

- ▶ Moderately destructed ETT were defined as teeth with
  - ▶ a MO/DO cavity with thin remaining axial walls (<2 mm) or
  - ▶ a MOD cavity.
- ▶ The teeth in this category have reduced fracture resistance due to the amount of tooth structure lost and would probably benefit from **cuspal coverage**.



# Severely destructed ETT

- ▶ Severely destructed ETT were defined as teeth with
  - ▶ **tooth structure loss beyond a MOD cavity.**
- ▶ The teeth in this category would have suffered from large amount of tooth structure loss and would definitely benefit from **cuspal coverage.**



# key modifying factors

- ▶ **parafunctional habits :**


Parafunctional habits should be taken into consideration when a decision is made about the need for cuspal coverage and the restorative material which could withstand such forces.

- ▶ **lateral occlusal forces.**

Lateral occlusal forces are more destructive to the tooth than axial occlusal forces.

- ▶ **the number of proximal contacts**

Having proximal contacts was reported to favorably dissipate the occlusal load to the adjacent teeth. Therefore, ETT with only one proximal contact or without adjacent proximal contacts are subjected to unfavorable distribution of occlusal forces.




## Step 2: Choosing a conservative treatment option for each clinical situation

- ▶ In addition, the most esthetic treatment option should also be considered if the tooth falls in the esthetic zone.
- ▶ It is also important to keep in mind that teeth with subgingival cavities due to caries or fractures are usually difficult to restore with adhesive restorations.
- ▶ This is attributed to the difficulty in achieving good isolation to obtain a dry field necessary for the bonding procedure. In these situations, the clinician should opt for a mechanically retained restoration.
- ▶ Otherwise, clinical crown-lengthening procedure might be considered to improve the margin location and facilitate the bonding procedure.

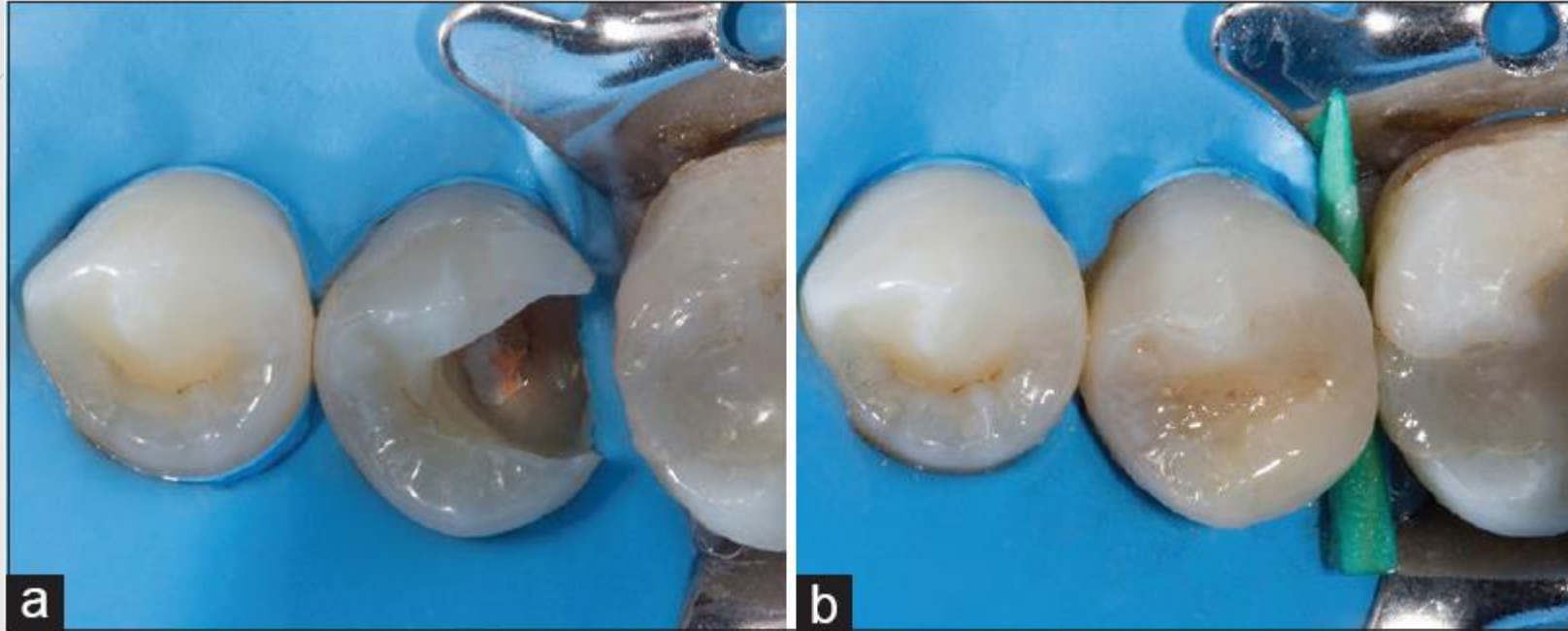




# *Minimally destructed teeth*

- ▶ **Direct restoration** specially intracoronal composite resin restorations
  - ▶ However, in the presence of a modifying factor **cuspal coverage** should be considered.
- 

## Minimally destructed teeth



- (a) Clinical assessment of the endodontically treated mandibular second premolar revealed a distoocclusal cavity and axial walls thickness ( $\geq 2$  mm).
- (b) In the absence of any modifying occlusal factors, the minimally destructed mandibular second premolar was restored with an intracoronal composite resin restoration



# *Moderately destructed teeth*

- ▶ **cuspal coverage**

- ▶ They could be managed through **mechanically retained indirect** restorations such as partial-coverage or full-coverage crowns

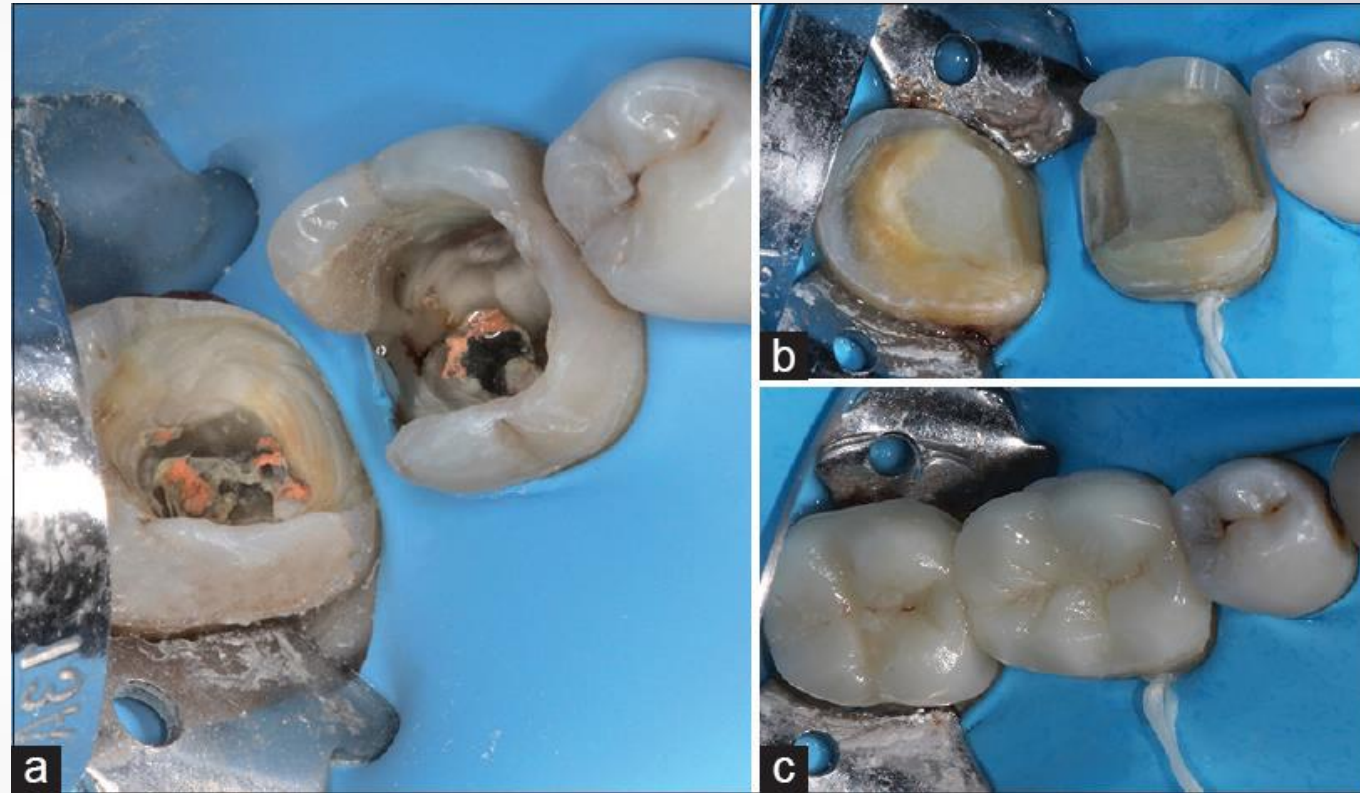
- ▶ They could also be managed through adhesively retained restorations such as adhesive onlays or overlays or endocrown.

# Moderately destroyed teeth

(a) Assessment of the amount of remaining tooth structure of the mandibular first and second molar teeth categorized them as moderately destroyed teeth.

(b) Following composite resin core buildup, preparations for two adhesive overlays were carried out.

(c) The moderately destroyed mandibular molars were restored with indirect adhesive ceramic overlays





# Severely destructed teeth

- ▶ **Post and core and crown**
- ▶ The **Nayyar technique** followed by a full-coverage crown could also be used.
  - ▶ In this technique, the restorative core material fills the pulp chamber and extends 2–3 mm into the coronal root canals
- ▶ Absence of adequate tooth structure, clinical **crown-lengthening** procedure might be needed to obtain sufficient tooth structure to provide the necessary **ferrule effect**.
- ▶ The full-coverage restoration leads to removal of significant amount of tooth structure, which is already scarce in such cases.
- ▶ In addition, such treatments are usually associated with an increase in the cost and time of treatment.



# *Severely destructed teeth*

## ► **The adhesive methods**

- fiber post, core, and partial- or full-coverage crowns.

The fiber posts unlike the metal posts depend on adhesion to the root dentine for its retention and have similar modulus of elasticity to that of dentine. The use of fiber posts is associated with more favorable types of failure and a higher chance of keeping the teeth restorable following failure


## ► **The endocrowns**

An endocrown is basically a type of restoration for ETT that consists of a core and a crown as a single unit, and extends into the pulp chamber.

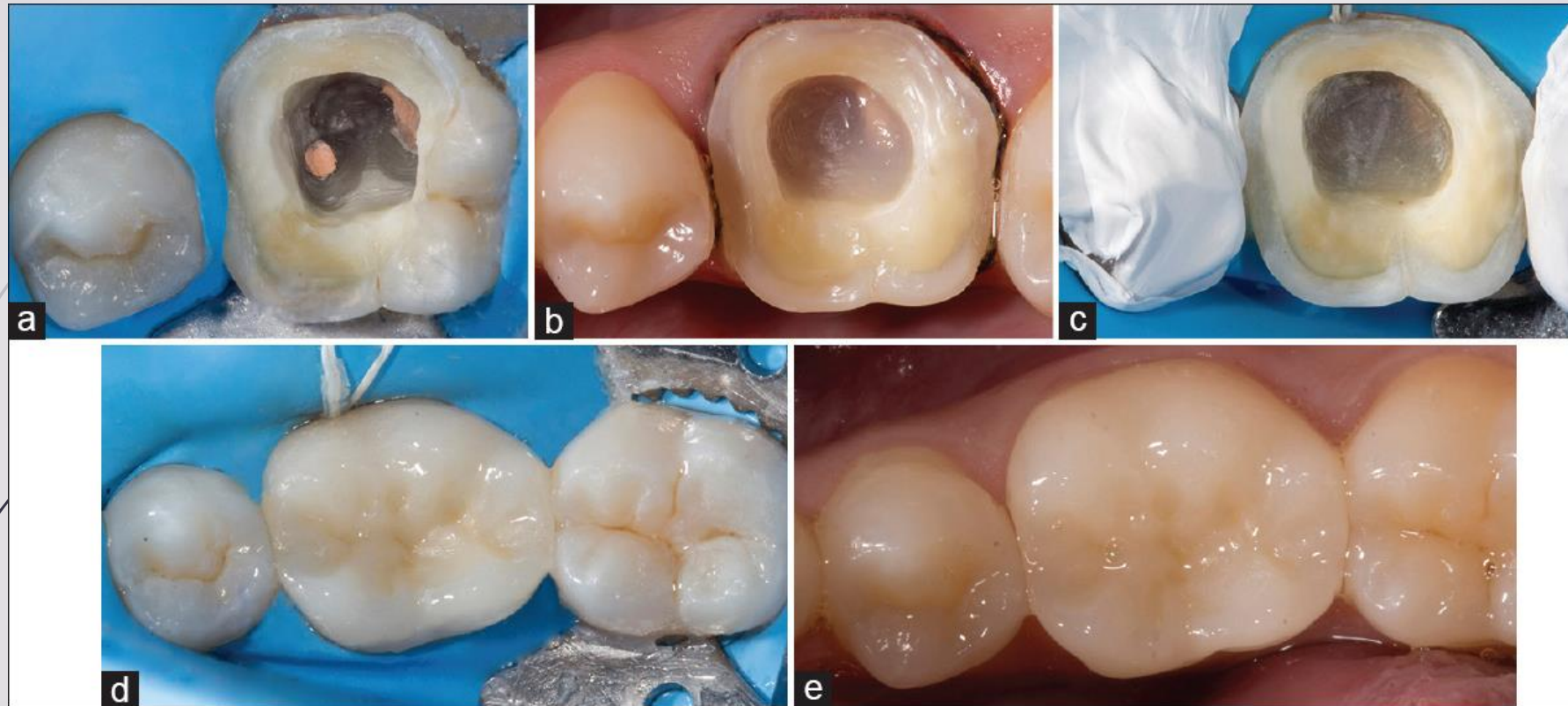




# *Severely destructed teeth*

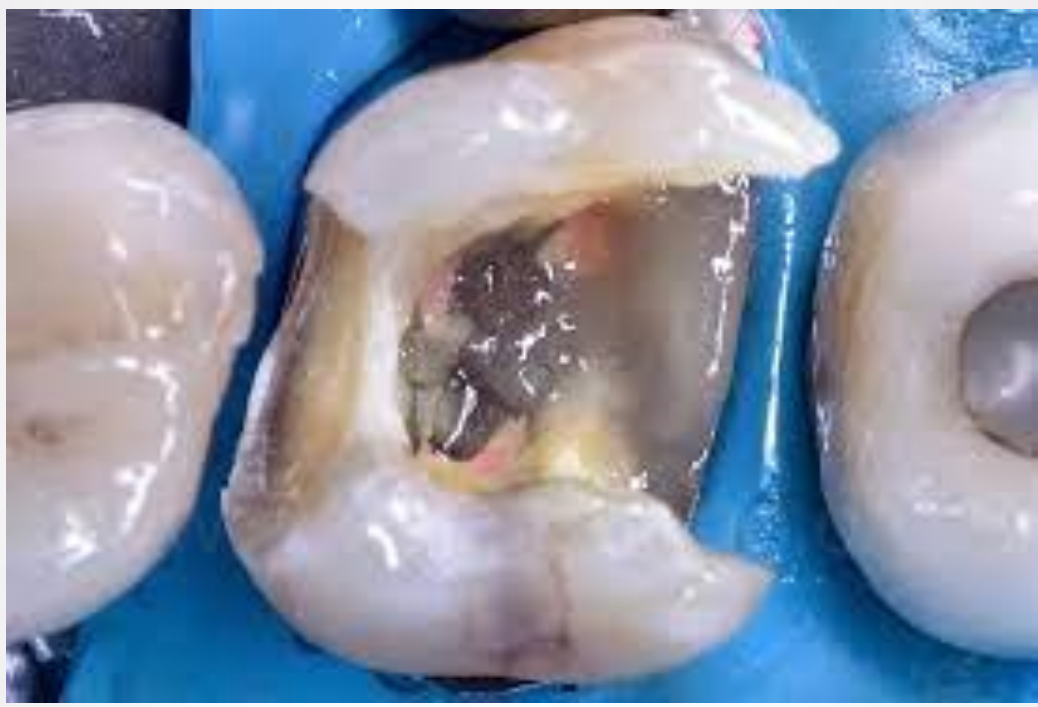

- ▶ **The endocrowns**
  - ▶ Retention is mainly obtained through adhesive resin cement (micro-mechanical retention).
  - ▶ Extra retention and stability is provided through the pulp chamber's axial walls (macro-mechanical retention).
  - ▶ Consequently, materials with the capability of bonding through resin cement to the tooth structure have been selected for use in endocrowns such as glass ceramic materials (feldspathic ceramic) and, more recently, lithium disilicate ceramic and computer-aided design-computer-aided manufacturing composite materials.
- 

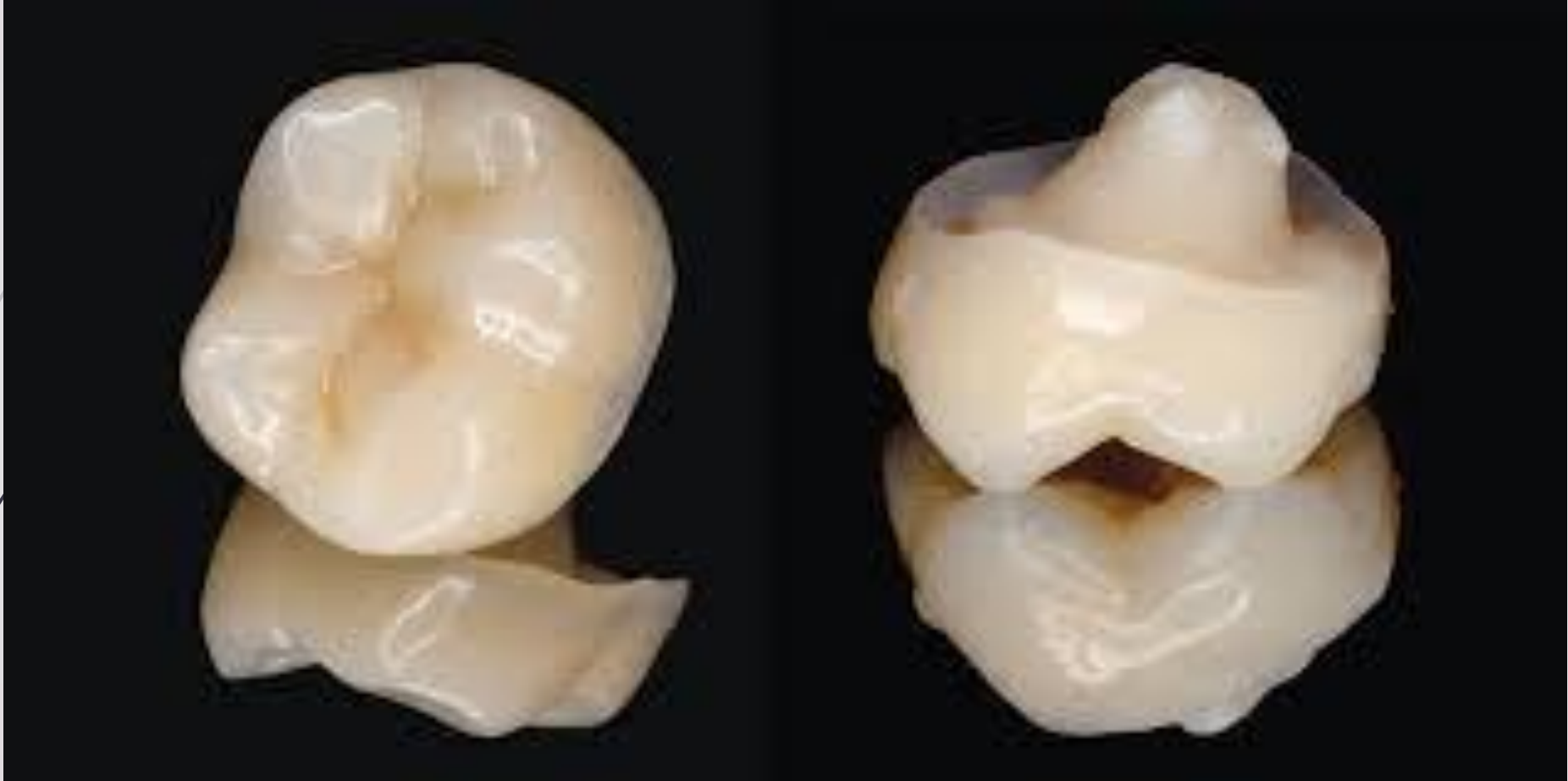# Severely destructed teeth

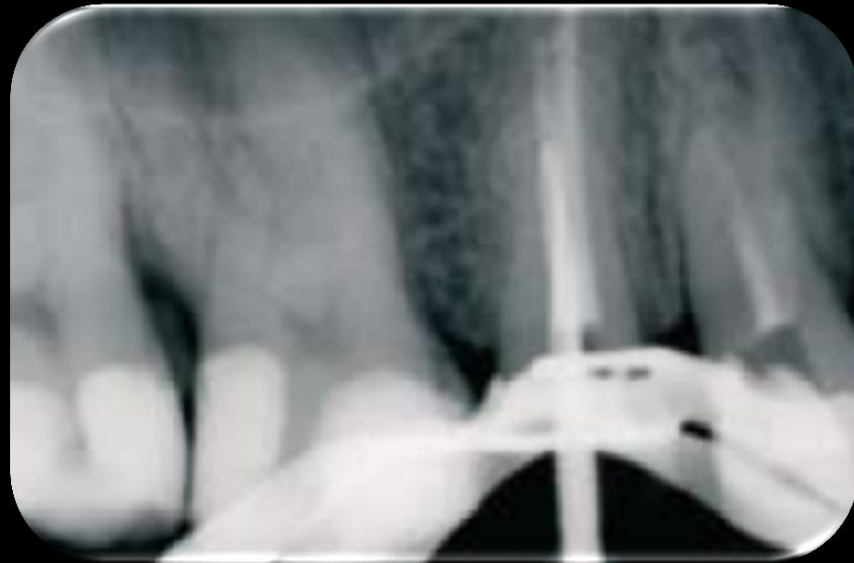
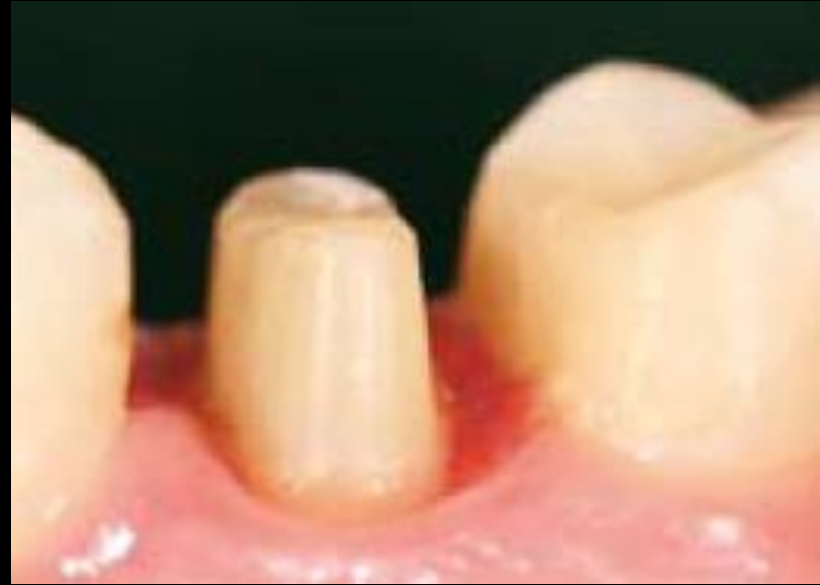
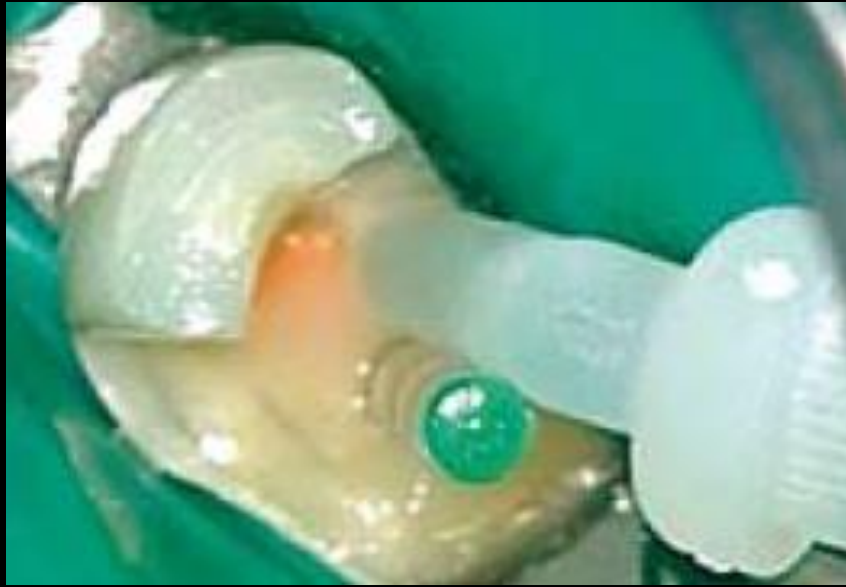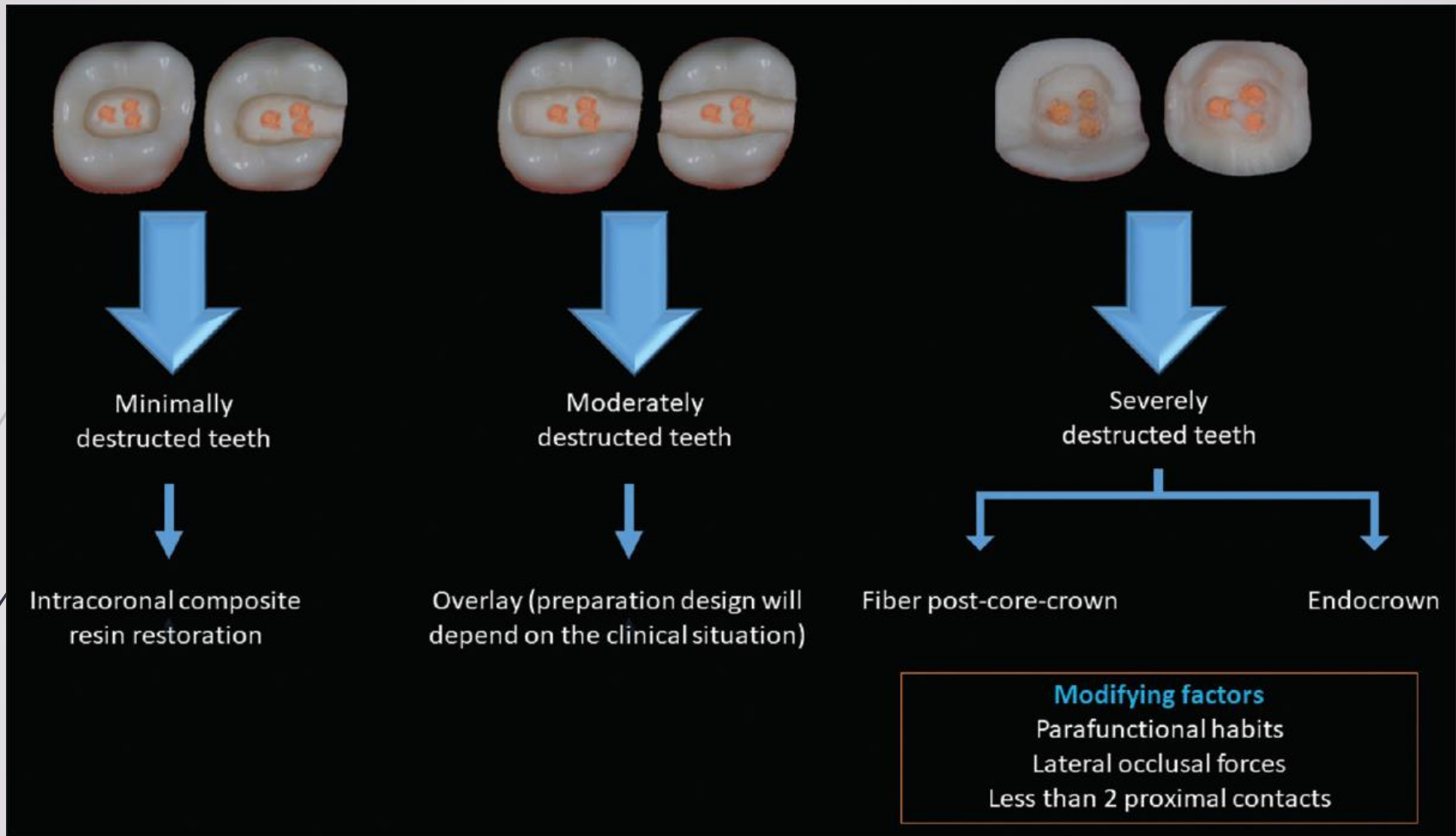
- (a) Assessment of the amount of tooth structure loss of the mandibular first molar categorized it as a severely destructed tooth.
- (b) Pulp floor was sealed, and a conservative preparation for an endocrown was carried out.
- (c) Preparation for the endocrown bonding procedure under rubber dam isolation.
- (d) The endocrown bonding procedure to mandibular first molar.
- (e) The endocrown 1 week following the bonding procedure to the mandibular first molar












Flowchart for the decisionmaking process for restoration of posterior endodontically treated teeth using adhesively retained restorations



# conclusion

- ▶ Minimally destructed ETT (teeth with an occlusal cavity or an MO/DO cavity with thick axial walls [ $\geq 2$  mm]) could be restored using intracoronal composite resin restorations
  - ▶ Moderately destructed ETT (teeth with an MO/DO cavity with thin axial walls [ $< 2$  mm] or an MOD cavity) could be restored using adhesive onlays/overlays
  - ▶ Severely destructed ETT (teeth with structure loss beyond an MOD cavity) could be restored using fiber post–core–crown or endocrowns
  - ▶ Modifying factors (bruxism, lateral occlusal forces, or  $< 2$  proximal contacts) should be taken into consideration during the decision-making process.
- 



**Thanks for your attention**